

De Garengeot Hernia: A Total Extraperitoneal Approach to a Femoral Hernia Repair

Kaitlyn Oldewurtel, DO, John Ground, DO, Marc Neff, MD

ABSTRACT

Introduction: A de Garengeot's hernia is a femoral hernia containing the appendix and accounts for approximately 0.8% of all femoral hernias.

Presentation of the Case: This paper describes a case of an 84-year-old female who presented with abdominal pain, believed to have an incarcerated femoral hernia. Patient underwent a hernia repair and was found to have a femoral hernia involving the appendix, a de Garengeot's hernia. The femoral hernia was repaired using a total extraperitoneal (TEP) approach.

Discussion: There are a variety of reported ways to repair a de Garengeot hernia. In this case, we discuss the successful use of the TEP approach to repairing a de Garengeot hernia.

Conclusion: Although rare, a de Garengeot hernia must remain on the differential when evaluating a patient for an incarcerated femoral hernia. A TEP approach provides the surgeon the ability to perform a variety of hernia repairs, regardless of what is encountered during the operation.

Key Words: De Garengeot hernia, Total Extraperitoneal, Femoral hernia, Acute appendicitis.

Rowan University School of Osteopathic Medicine, Stratford, NJ. (Drs. Oldewurtel and Ground)

Jefferson Health New Jersey, Department of Surgery, Stratford, NJ. (Dr Neff)

This is an open-access article distributed under the terms of the Creative Commons Attribution-Noncommercial-ShareAlike 3.0 Unported license (<https://creativecommons.org/licenses/by-nc-sa/3.0/>), which permits unrestricted non-commercial use, distribution, and reproduction in any medium, provided the original author and source are credited.

Disclosure: none

Funding sources: none

Conflict of interests: none.

Informed consent: Dr. Kaitlyn Oldewurtel declares that written informed consent was obtained from the patient/s for publication of this study/report and any accompanying images.

Address correspondence to: Dr. Kaitlyn Oldewurtel, Rowan University School of Osteopathic Medicine, 42 E. Laurel Rd., Suite 3610, Stratford, NJ 08084, Phone: 856-566-6875, Fax: 856-566-6873, E-mail: Oldewurtk2@rowan.edu.

DOI:10.4293/CRSLS.2021.00088

© 2022 by SLS, Society of Laparoscopic & Robotic Surgeons. Published by the Society of Laparoscopic & Robotic Surgeons.

INTRODUCTION

A de Garengeot's hernia is a femoral hernia which contains a portion or the entirety of the appendix.¹ De Garengeot hernias account for approximately 0.8% of all femoral hernias.² In a majority of cases, a de Garengeot hernia is discovered intraoperatively when a patient undergoes repair of an incarcerated femoral hernia. Computed tomography (CT) imaging may not allow for identification of structures contained within the femoral hernia. We present a case of a de Garengeot hernia discovered intraoperatively and its repair, utilizing the Total Extraperitoneal (TEP) approach.

PRESENTATION OF CASE

An 84-year female presented to the emergency department (ED) with complaints of sudden, sharp right lower quadrant abdominal pain and nausea. At the initiation of the pain, she noticed a bulge in her right groin, which she had never appreciated before. She had not passed flatus or had a bowel movement since onset of pain. Initial patient laboratory results were significant for leukocytosis. Patient underwent a CT scan of the abdomen and pelvis with intravenous contrast, which demonstrated an incarcerated femoral hernia containing a loop of small bowel causing proximal small bowel obstruction (**Figure 1**). Following the CT scan, prior to evaluation by the surgical team, the ED physician was able to reduce the incarcerated hernia and the patient's symptoms resolved. The patient was admitted to the hospital and was optimized medically prior to any surgical repair.

Initially, patient underwent a diagnostic laparoscopy to inspect the abdomen and determine the appropriate operative approach. At this time, a femoral hernia containing the appendix was identified (**Figure 2**). Additional ports were placed and reduction of the femoral hernia was attempted, but found to be incarcerated. At that time, the abdomen was desufflated. Separate incisions were made and a totally extraperitoneal approach was attempted utilizing a balloon dilator. In the preperitoneal space the femoral hernia was reduced, and a mesh was placed (**Figure 3**). Once the mesh was placed in position, the abdominal cavity was reinsufflated. Using a separate set of instruments, the appendectomy was performed. The appendix was identified, the mesentery was dissected out,

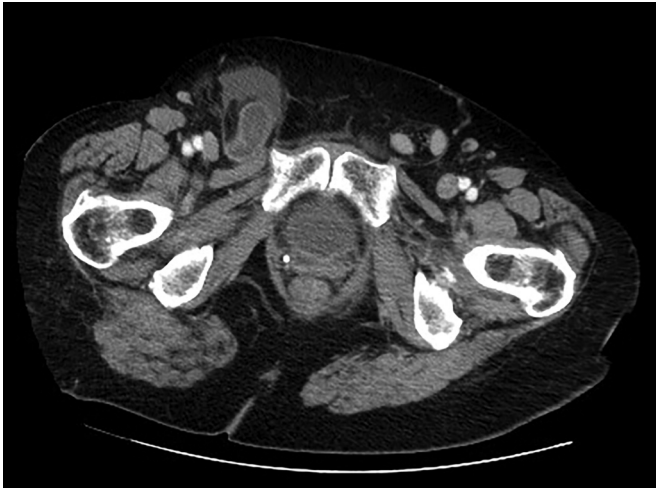

Figure 1. Computed Tomography scan demonstrating incarcerated femoral hernia containing small intestines.

and transected using an Endo GIA™ stapler. The appendix was completely intact and no spillage occurred. After inspecting the abdomen entirely, the abdomen was again desufflated. Completion of the femoral hernia in the preperitoneal spaced was performed. The mesh was not tacked in place. All ports were closed and covered with Dermabond®. The patient was discharged home the following day.

DISCUSSION

There are a variety of surgical approaches to treatment of de Garengoot hernias.³ Of the approximately 90 cases reported, there was only one publication which described a TEP approach to repair a femoral hernia defect.⁴ The TEP repair allows for the ability to repair several different defects, including femoral, inguinal, and obturator hernias. In addition to the TEP approach, surgeons have repaired a de Garengoot

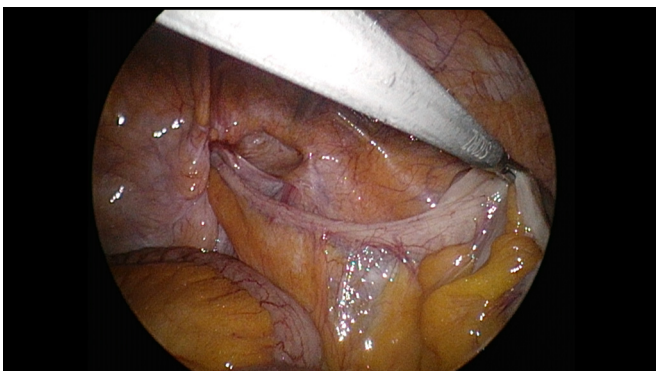


Figure 2. De Garengoot hernia identified intraoperatively as the appendix is visualized entering the femoral canal.

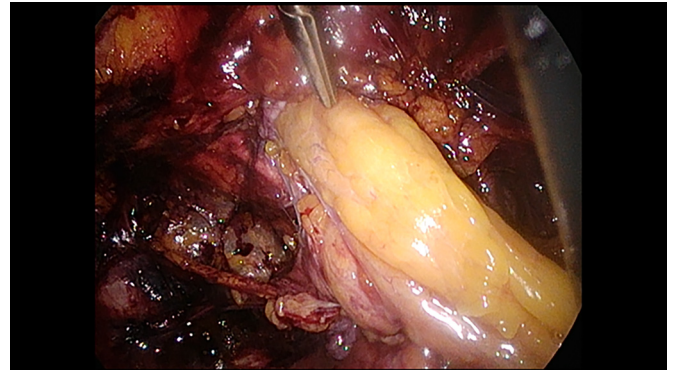


Figure 3. Prior to the appendectomy, the femoral hernia was reduced utilizing a total extraperitoneal approach.

hernia utilizing different surgical approaches, including laparotomy, open inguinal with diagnostic laparoscopy, open inguinal repair, preperitoneal, or a combination of approaches. The decision for which operative approach to utilize was dependent on a variety of factors, including concerns of perforation or necrotic bowel, as well as findings on CT imaging. Diagnostic laparoscopy was performed in several cases due to inability to identify the pathology on pre-operative imaging; this allowed for the surgeon to visualize the problem and determine the proper approach for repair. In the instance of our case, a diagnostic laparoscopy was performed initially to determine further operative planning; pre-operative imaging did not fully identify the pathology, therefore, direct visualization aided in the diagnosis of a de Garengoot hernia.

In the previous published case describing a TEP repair, the authors performed the diagnostic laparoscopy and laparoscopic appendectomy first, then closed the peritoneum prior to the TEP femoral hernia repair. The argument for this approach was to prevent placing mesh in a potentially contaminated environment; therefore, the extraperitoneal femoral hernia repair was performed after the peritoneum had been closed. As in our case, the appendectomy was performed prior to fixation of the mesh in the extraperitoneal space. Although a majority of manipulation of the mesh occurred prior to removal of the appendix, there was no spillage of contents during the appendectomy. A separate set of instruments was used to perform the appendectomy in order to minimize the overlap between a clean portion of the procedure with a clean-contaminated portion. The TEP was performed using different incisions from the appendectomy in order to prevent the potential of cross-contamination. As long as there is no spillage, placement of mesh before or after appendectomy should be safe and limit concern of infection.

In conclusion, although the incidence is rare, a de Garengeot hernia must always remain on the differential when a surgeon approaches an incarcerated femoral hernia. Often times, the diagnosis of a de Garengeot hernia occurs intraoperatively, regardless of prior imaging findings. The operative approach to these femoral hernia repairs will often be dictated by what is discovered intraoperatively. If an appendectomy is necessary, as in this case, the surgeon must take into consideration the importance of avoiding cross contamination when placing mesh to repair the hernia. The TEP approach provides the surgeon feasibility to perform a variety of hernia repairs, regardless of what is encountered during the procedure.

References:

1. Akopian G, Alexander M. De Garengeot hernia: appendicitis within a femoral hernia. *Am Surg.* 2005;71(6):526–527.
2. Nguyen E, Komenaka I. Strangulated femoral hernia containing a perforated appendix. *Canadian Journal of Surgery Feb.* 2004;47(1):68–69. 14997930.
3. Linder S, Linder G, Mansson C. Treatment of de Garengeot's hernia: a meta-analysis. *Hernia.* 2019;23(1):131–141.
4. Beysens M, Haeck L, Vindevoghel K. Laparoscopic appendectomy combined with TEP for de Garengeot hernia: case report. *Acta Chirurgica Belgica.* 2013;113(6):468–470.