

Multiple Myeloma Plasmacytoid Infiltration of the Gallbladder Presenting as Acute Cholecystitis

Fadi Alyass, Patrick N. Narh-Martey, MD, FACS

ABSTRACT

Secondary distal plasmacytoma that arise from multiple myeloma is a common hematological malignancy that manifests in later stages of the disease. These plasmacytomas are known to cause extensive systemic organ damage. When extramedullary plasmacytomas reach the gallbladder or biliary ducts, expansion can mimic acute acalculous cholecystitis or cholangiocarcinoma. We report a case of a 56-year-old female with a history of aggressive course IgA κ chain multiple myeloma who presented with right upper quadrant abdominal pain with nausea and vomiting for one week duration. Her laboratory panel revealed liver function tests consistent with gallbladder etiology. Abdominal ultrasound and CT showed no evidence of cholelithiasis precluding to acute acalculous cholecystitis. Initial medical management did not show any improvement. A robotic cholecystectomy was performed, and a pathology review of the specimen found a neoplastic stricture of the gallbladder fundus, the histological evaluation of which revealed plasmacytoid cells originating from her primary multiple myeloma diagnosis. The patient's

condition declined following surgery, postoperative presentation included metastatic liver thrombosis mimicking cholangiocarcinoma and the patient later expired with palliative care.

Key Words: Acute cholecystitis, Multiple myeloma, Extramedullary plasmacytoma, Robotic laparoscopy.

INTRODUCTION

Multiple myeloma (MM) is a malignant plasma cell dyscrasia in which monoclonal plasma cells in the bone marrow proliferate uncontrollably. This is the second most common hematological cancer and most common primary tumor of bone. Multiple myeloma comes without any known genetic component or definitive environmental risk factors.¹

The pathophysiology of multiple myeloma is shown when bone marrow aspirate is seen to have 10% or greater plasma cells (normally 5%), which become neoplastic and monoclonal. These monoclonal plasma cells proliferate in bone marrow and produce abnormal antibodies as well as light chains called paraproteins, which are a feature of diagnosing multiple myeloma.^{2,3}

In the early stage of the plasma cell dyscrasia, neoplastic plasma cells are usually limited to the bone marrow (solitary plasmacytoma of bone). In some cases, the plasmacytoma can disseminate via hematogenic route to soft tissue called a solitary extramedullary plasmacytoma. These extramedullary plasmacytomas usually have a more aggressive course and worse prognosis.^{1,4-7}

The involvement of the gallbladder and biliary ducts by extramedullary plasmacytomas is very rare.^{6,8-11} Preoperative diagnosis of any hematomalymphoid malignancy of the gallbladder is very difficult to reach due to the rarity of the diseases. In the aspect of plasmacytoma of the gallbladder and biliary tree that mimics acute cholecystitis and cholangiocarcinoma, surgical resection followed by chemotherapy is considered a valid treatment for patients.^{9,12}

Trinity Medical Science University, School of Medicine, (International) Ribishi, St. Vincent and the Grenadines, West Indies, (United States) Roswell, Georgia USA (F. Alyass).

Houston Medical Center, General Surgery, Department of Surgery, Wamer Robins, Georgia USA (Dr. P. N. Narh-Martey).

This is an open-access article distributed under the terms of the Creative Commons Attribution-Noncommercial-ShareAlike 3.0 Unported license (<https://creativecommons.org/licenses/by-nc-sa/3.0/>), which permits unrestricted non-commercial use, distribution, and reproduction in any medium, provided the original author and source are credited.

Disclosure: none.

Funding/Financial support: none.

Conflicts of interest: The authors declare no conflict of interest.

Informed consent: Fadi Alyass declares that written informed consent was obtained from the patient's for publication of this study/report and any accompanying images.

Address correspondence to: Fadi Alyass, Trinity Medical Science University, School of Medicine, 925 Woodstock Road, Suite 200 Roswell, Georgia 30075, Telephone: 248-703-5474, E-mail: fadi.alayass.22@trinitysom.net.

DOI:10.4293/CRSLS.2021.00049

© 2021 by SLS, Society of Laparoscopic & Robotic Surgeons. Published by the Society of Laparoscopic & Robotic Surgeons.

CASE Presentation

A 56-year-old African-American female with past medical history of aggressive immunoglobulin A (IgA) κ multiple myeloma diagnosed 7 years prior presented to the emergency department with unrelenting epistaxis and anemia. Quantitative serum immunoglobulin tests at that time revealed the presence of paraproteins and abnormal immunoglobulins as follows in **Table 1**.

Following this interpretation, a skeletal survey was conducted that found chronic degenerative changes but no evidence of any lytic or blastic lesions as well as any acute processes. Bone marrow biopsy was done to categorize the abnormal immunoglobulin findings that found CD138-positive plasma cells comprising 16% of the aspirate. These results are positive for diagnosis of plasma cell dyscrasia. Flow cytology found the monoclonal plasma cells as κ positive. A fluorescent in situ hybridization (FISH) performed on the CD138-positive plasma cells revealed results consistent with plasma cell neoplasm including evidence of TP53 deletion, which is attributed with higher risk as well as RB1 deletion. The patient's chemotherapy cycles consisted of bortezomib and dexamethasone, which were administered as an outpatient. One year prior the patient began a trial chemotherapy regimen at another university hospital. However, two months prior to current presentation with acute cholecystitis the patient had been noncompliant with this regimen as well as all other multiple myeloma treatments.

On current presentation, the patient presented to emergency department for right upper quadrant abdominal pain with nausea and vomiting for one week duration, which was aggravated by meals. She also complained of lack of

bowel movements for one week duration that the patient attributed to taking oxycodone for pain. The patient was in mild distress but alert and oriented with stable vital signs. Initial pertinent labs are represented in **Table 2**.

Physical examination revealed a tender right upper quadrant with positive Murphy's sign. An abdominal ultrasound showed an enlarged gallbladder with thickening of the gallbladder wall without evidence of cholelithiasis. A subsequent abdominal CT without contrast revealed similar findings to the abdominal ultrasound as well as enlarged right and left portal veins without liver mass. Blood cultures were obtained, the patient was placed on intravenous Piperacillin/Tazobactam regimen and put on a clear liquid diet with an initial goal to medically manage an initial running diagnosis of acute acalculous cholecystitis.

Blood cultures were initially contaminated and with repeat cultures returning negative for organisms. With medical management not showing any clinical improvement, a decision was made to perform a laparoscopic robotic cholecystectomy.

Operative gross examination of the gallbladder specimen showed a grossly enlarged, acutely inflamed with thick chronic inflammatory rind that complicated the dissection of the gallbladder. The cystic artery also appeared to be constricted and atrophied per dissection (**Figure 1**). The procedure had no complications, the patient tolerated it well and was later discharged.

Pathological evaluation revealed that the gallbladder wall was diffusely infiltrated by malignant appearing plasmacytoid cells with probable stricture of the gallbladder

Table 1.
Patient's Initial Immunologic Panel for Multiple Myeloma Diagnosis

| | | |
|--|--|---------------------------|
| IgG Total | 219 mg/dL | (normal 694 – 1618 mg/dL) |
| IgA Total | 10,862 mg/dL | (normal 81 – 463 mg/dL) |
| IgM Total | 18 mg/dL | (normal 48 – 271 mg/dL) |
| Immunofixation electrophoresis: paraproteins | Detected | |
| Immunofixation electrophoresis: interpretation | Data suggests monoclonal gammopathy: IgA type κ | |
| Reticulin IgA antibody | Negative | |
| Tissue transglutaminase IgA | Negative | |
| Parietal cell antibody titer | <3.0 U/mL | (normal <4.0 U/mL) |
| Antigliadin IgG antibody | 1 U/mL | (normal <11 U/mL) |
| Antigliadin IgA antibody | 83 units | (normal <20 units) |
| Intrinsic factor block antibody | Detected | |

Table 2.
Patient's Initial Laboratory Workup for Acute Cholecystitis Presentation

| | | |
|----------------------------|------------|-----------------------------|
| Alanine aminotransferase | 115 U/L | (normal 7 – 52 U/L) |
| Aspartate aminotransferase | 121 U/L | (normal 13 – 39 U/L) |
| Total bilirubin | 1.1 mg/dL | (normal 0.3 – 1.0 mg/dL) |
| Alkaline phosphatase | 1,482 U/L | (normal 34 – 104 U/L) |
| Albumin | 3.2 g/dL | (normal 3.5 – 5.7 g/dL) |
| Globulin | 5.2 g/dL | (normal 2.1 – 3.9 g/dL) |
| Hemoglobin | 11.4 g/dL | (normal 11 – 15 g/dL) |
| White blood cell count | 6,000 /cmm | (normal 4,000 – 11,000/cmm) |
| Neutrophil (%) | 59.5% | (normal 40 – 79%) |
| Lymphocyte (%) | 15.3% | (normal 14.5 – 48.7%) |
| Monocyte (%) | 8.2% | (normal 4 – 11%) |
| Eosinophil (%) | 15.4% | (normal 0.4 – 7.3%) |
| Basophil (%) | 1.6% | (normal 0.0 – 1.6%) |
| Blood urea nitrogen | 13 mg/dL | (normal 7 – 25 mg/dL) |
| Creatinine | 0.58 mg/dL | (normal 0.60 – 1.2 mg/dL) |
| BUN/Cr ratio | 22.4 | (normal 12 – 20) |
| Procalcitonin | 5.17 ng/mL | (normal 0.00 – 1.99 ng/dL) |

fundus. Immunohistochemical stains confirmed these were plasma cells in origin (CD138 strong positive). The plasma cells were shown to have a stronger κ than λ via flow cytology, consistent with the patient's initial neoplastic plasma cells.

Following cholecystectomy, the patient presented again to the emergency department complaining of abdominal pain one week post cholecystectomy and had a repeat abdominal CT. This revealed a mild hypodense fluid collection in gallbladder fossa signifying a loculated hematoma. One month following cholecystectomy she again presented to the emergency department with metastatic thrombosis of the portal vein mimicking cholangiocarcinoma as well as metastasis in the liver lobes. Two months following cholecystectomy, the patient presented again to the emergency department for hypoxemia where she proceeded to hospice care and expired with comfort measures.

DISCUSSION

Extramedullary disease in plasma cell myeloma is an uncommon phenomenon with multiple myeloma and demonstrates decreased survival in affected patients. However, these extramedullary plasmacytomas have been increasingly detected with multiple myeloma.⁶ The accepted etiology is that these extramedullary plasmacytomas are a direct

extension in bone. Due to the vascular access of bone, hematogenous spread is thought to occur as this route to spread to distal organs.¹³

Extramedullary plasmacytomas are observed in 7% – 18% of patients with multiple myeloma at the time of diagnosis.¹⁴ Extrasosseous spread occurs in up to 66% of patients with distant metastasis including spleen, liver, and lymph nodes.¹⁵

Gallbladder or biliary involvement by extramedullary plasmacytoma associated with multiple myeloma is rare and has been described in these case reports. This involvement is shown to mimic primary cholangiocarcinoma, primary gallbladder cancer, or other common causes of inflammatory, infectious, or obstructive diseases of gallbladder and biliary tracts.^{7,10,11,16–19} Therefore, due to the rarity of this presentation, extramedullary plasmacytomas are not considered in the differential diagnosis when a patient with a history of multiple myeloma presents with biliary-like diseases.¹²

CONCLUSION

Solitary plasmacytomas are considered distinct clinical diseases from multiple myeloma with different treatments and prognoses. Secondary plasmacytomas are usually associated with a more aggressive course. Gallbladder and biliary involvement for extramedullary

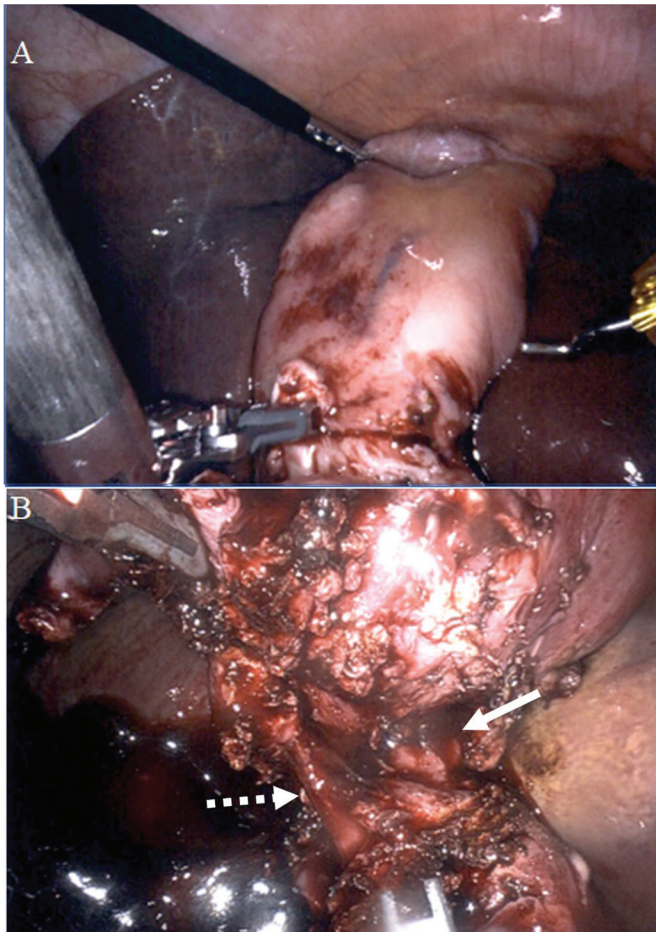


Figure 1. Operative photos of plasmacytoid inflamed gallbladder. Note. Intraoperative endoscopic photos of (A) acutely inflamed gallbladder with thick inflammatory rind and (B) the cystic duct (solid arrow) is visualized with cystic artery (dashed arrow) appearing to be constricted and atrophied.

plasmacytoma is a rare occurrence only described in few case reports but should be included with a differential diagnosis on any patient presenting with gallbladder and biliary symptoms in the presence of moderate to advanced multiple myeloma in an effort to advance patient care and better treat their disease course with adjuvant and neoadjuvant therapies prior to surgical treatment and following resection, respectively, specifically in the setting for increased risk for thrombotic events.

References:

1. Abt AB, Deppisch LM. Multiple myeloma involving the extrahepatic biliary system. *J Mt Sinai Hospital NY.* 1969; 36:48–54.

2. Abughanimeh O, Qasrawi A, Omar MA, Bahaj W, Ghanimeh MA. A case of multiple myeloma associated with extramedullary plasmacytoma of the gallbladder manifesting as acute cholecystitis. *Cureus.* 2018;10(5):e2688.

3. Fukatsu H, Hiramatsu Y, Takagi S, Morishita H. Multiple myeloma involving the extrahepatic bile duct. *Intern Med.* 2013; 52(7):829–830.

4. Heckman M, Uder M, Grgic A, Adrian N, Bautz W, Heinrich M. Extraosseous manifestation of multiple myeloma with unusual appearance in computed tomography, case report. *Rontgenpraxis.* 2008;56(6):249–253.

5. Huang H, Bazerbachi F, Mesa H. Asymptomatic multiple myeloma presenting as a nodular hepatic lesion: a case report and review of the literature. *Ochsner J.* 2015;15: 457–467.

6. Hwang DW, Lim C-S, Jang J-Y, et al. Primary hematolymphoid malignancies involving the extrahepatic bile duct or gallbladder. *Leuk Lymphoma.* 2010;51(7):1278–1287.

7. Kondo H, Kainuma O, Itami J, Minoyama A, Nakada H. Extramedullary plasmacytoma of the maxillary sinus with later involvement of the gall bladder and subcutaneous tissues. *J Clin Oncol.* 1995;7(5):330–331.

8. Majerovic M, Bogdanic B, Drinkovic N, Kinda SB, Jakic-Razumovic J, Gasparovic V. Extramedullary plasmacytoma imitating neoplasm of the gallbladder fossa after cholecystectomy. *Coll Anthropol.* 2012;36:331–333.

9. Moreau P, San Miguel J, Sonneveld P, ESMO Guidelines Committee, et al. Multiple myeloma: ESMO Clinical Practice Guidelines for diagnosis, treatment and follow-up. *Ann Oncol.* 2017;28(suppl_4):iv52–iv61.

10. Mouchli M, Grider DJ, Yeaton P. Gallbladder metastases: a report of two cases. *Case Rep Oncol.* 2019;12(1):235–240.

11. Oshima K, Kanda Y, Nannya Y, et al. Clinical and pathologic findings in 52 consecutively autopsied cases with multiple myeloma. *Am J Hematol.* 2001;67(1):1–5.

12. Phekoo KJ, Schey SA, Richards MA, et al. On behalf of Consultant Haematologists, South Thames Haematology Specialist Committee. A population study to define the incidence and survival of multiple myeloma in a National Health Service Region in UK. *Br J Haematol.* 2004;127(3):299–304.

13. Raab MS, Podar K, Breitkreutz I, Richardson PG, Anderson KC. Multiple myeloma. *Lancet.* 2009;374(9686):324–339.

14. Rajkumar SV, Dimopoulos MA, Palumbo A, et al. International Myeloma Working Group updated criteria for the diagnosis of multiple myeloma. *Lancet Oncol.* 2014;15(12): e538–e548.

15. Rotaru I, Găman G, Dumitrescu D, Foarfă C. Secondary plasma cell leukemia. *Rom J Morphol Embryol.* 2012;53(4):1073–1056.

16. Schuster D, Klosterhalfen B, Fiedler C, Prescher A. Metastasis of medullary plasmacytoma as the cause of acute cholecystitis. *Dtsch Med Wochenschr.* 2007;132(12): 612–615.
17. Sobol H, Vey N, Sauvan R, Philip N, Noguchi T, Eisinger F. Familial multiple myeloma: a family study and review of the literature. *J Natl Cancer Inst.* 2002;94(6):461–462.
18. St Romain P, Desai S, Bean S, Jiang X, Burbidge RA. Extramedullary plasmacytoma of the gallbladder diagnosed by endoscopic ultrasound fine needle aspiration (EUS-FNA). *J Gastrointest Oncol.* 2015;6(2):E7–9.
19. Wirk B, Wingard JR, Moreb JS. Extramedullary disease in plasma cell myeloma: the iceberg phenomenon. *Bone Marrow Transplant.* 2013;48(1):10–18.