

# Laparoscopic Revision of Nissen to Partial Fundoplication 20 Years After Initial Surgery as an Infant

Brianne Wiemann, MD, Cyril Kamyra, MD, Edward Auyang, MD  
Department of Surgery, University of New Mexico Hospital, Albuquerque, NM.

## ABSTRACT

We report a case of a 21-year-old male who presented with adult-onset dysphagia after previous Nissen fundoplication initially created at age 10.5 months. The patient first presented one year ago to a different hospital, where he underwent extensive workup for his symptomatology. Physiologic tests performed were esophagogastroduodenoscopy (EGD), abdominal ultrasound, hepatobiliary iminodiacetic acid scan, esophageal manometry, and lactulose breath test. The EGD identified stricture at the level of the gastroesophageal junction. The other studies did not reveal other physiologic causes for his symptoms. The patient then presented to our institution, at which time a repeat EGD showed evidence of tight Nissen fundoplication. The patient subsequently underwent laparoscopic exploration, which revealed that the fundoplication had been partially disrupted, herniated, and twisted causing a long-segment distal stricture. To alleviate the patient's presenting symptom of dysphagia as well as prevent possible future reflux, it was decided to convert repair the hernia and revise the Nissen into a partial fundoplication. This was successfully accomplished laparoscopically with subsequent resolution of the patient's symptoms.

**Key Words:** Pediatric GERD, Nissen fundoplication, Toupet fundoplication, Dysphagia.

**Citation** Wiemann B, Kamyra C, Auyang E. Laparoscopic revision of nissen to partial fundoplication 20 years after initial surgery as an infant. CR<sup>SLS</sup> e2021.00002. DOI: 10.4293/CRSLS.2021.00002.

**Copyright** © 2021 by SLS, Society of Laparoscopic & Robotic Surgeons. This is an open-access article distributed under the terms of the Creative Commons Attribution-Noncommercial-ShareAlike 3.0 Unported license, which permits unrestricted noncommercial use, distribution, and reproduction in any medium, provided the original author and source are credited.

Disclosure: none.

Funding/Financial Support: none.

Conflicts of Interest: none.

Address correspondence to: Dr. Brianne Wiemann, MD, Department of Surgery, University of New Mexico Hospital, 2ACC, Albuquerque, NM 87131, Telephone: 505-272-6487, Fax: 505-272-4156, E-mail: BWiemann@salud.unm.edu.

## INTRODUCTION

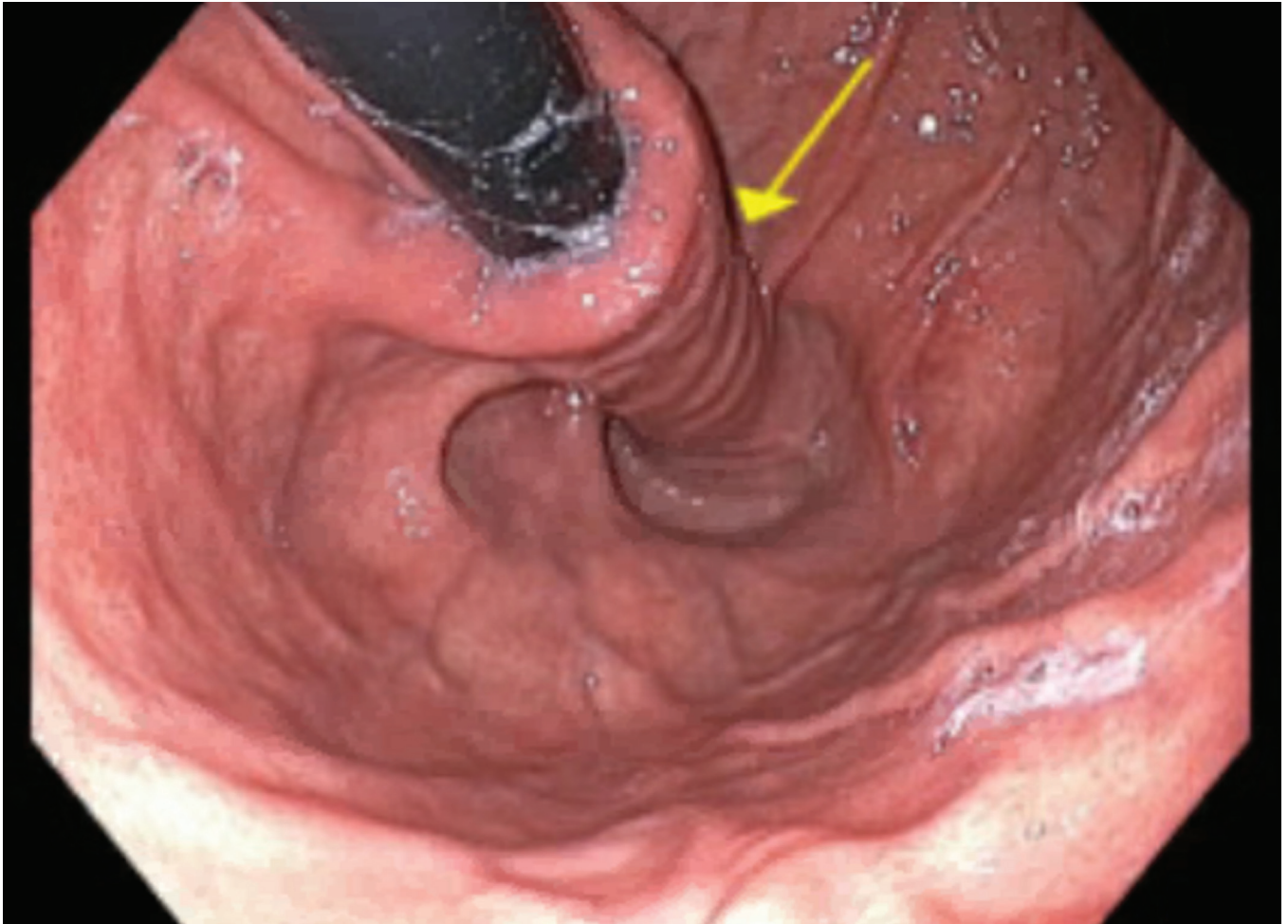
First introduced as a treatment for gastroesophageal reflux disorder (GERD) in 1991 by Dallemange et al., laparoscopic Nissen fundoplication in pediatric patients has since become the standard of care for children with GERD refractory to medical management.<sup>1</sup> It is estimated that GERD affects 7% -20% of the pediatric population<sup>2</sup> and approximately 25% - 36% of these children undergo surgical intervention to decrease GERD symptomatology.<sup>3</sup> However, current literature suggests that there is a higher rate of postoperative complications and recurrence of initial symptoms in the pediatric population compared to those in adults undergoing the same surgical procedure.<sup>3</sup> For patients who undergo their index operation at an age

younger than 1 year old, the need for redo of a Nissen fundoplication may be as high as 6.4%, significantly higher than that seen in the adult population.<sup>1</sup>

Here, we report a case of successful conversion of a Nissen fundoplication to partial posterior fundoplication in a patient who suffered from nausea 20 years after his index operation. This is a unique presentation as pediatric patients typically outgrow their Nissen fundoplication and thus should not have delayed dysphagia.

## CASE DESCRIPTION

This is a 21-year-old male who initially underwent laparoscopic Nissen fundoplication at age 10.5 months in

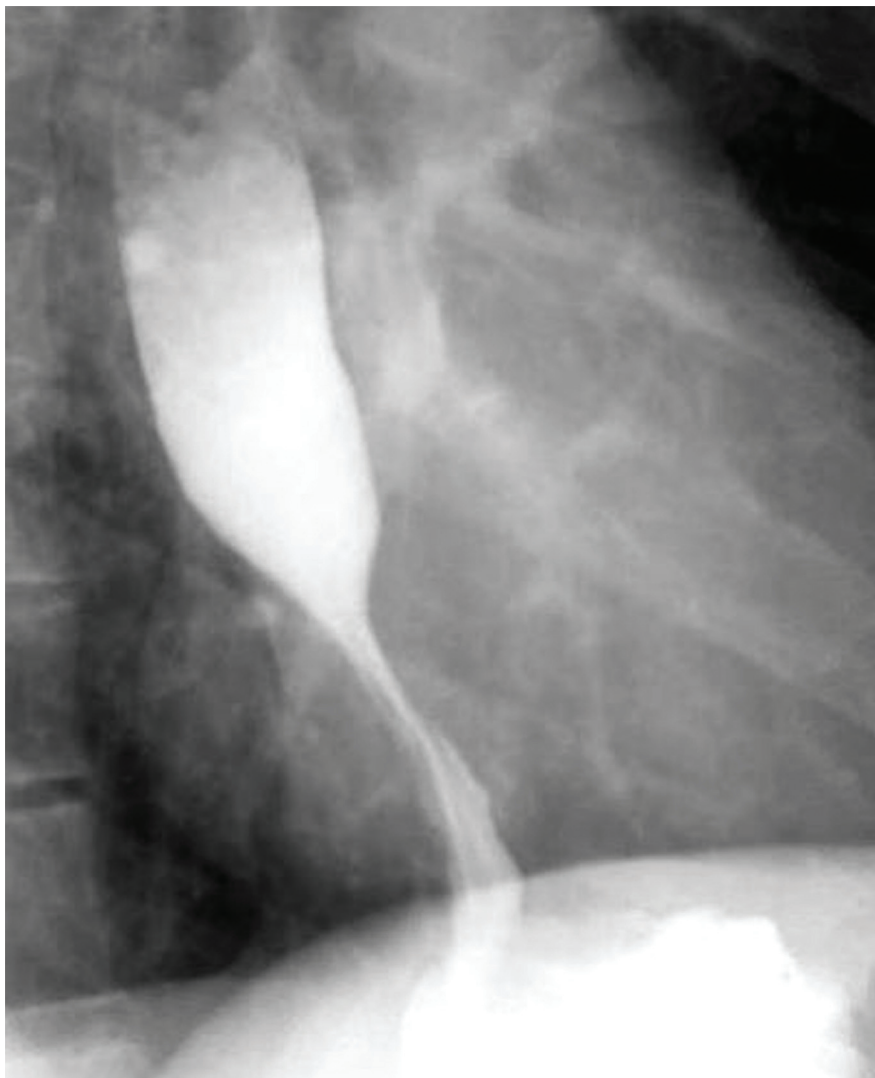

**Figure 1.** The Nissen fundoplication wrap as visualized on the patient's pre-operative esophagogastroduodenoscopy. The wrap is excessively tight.

1999. The patient's symptoms were feeding intolerance with failure to thrive at a weight of 12 lbs. The Nissen wrap was performed over a 24fr bougie. A gastrostomy tube was placed at that time to aid in enteral feeding and was later removed with subsequent tract closure.

By age 19, the patient began reporting persistent nausea and dry heaving, without emesis. His primary complaint was dysphagia to both solids and liquids. He was seen by gastroenterology specialists in 2019, at which time an esophagogastroduodenoscopy (EGD) showed LA Grade A esophagitis, gastritis, and a small hiatal hernia (**Figure 1**). His esophagus was dilated to 15mm and biopsies taken at this time were negative for *H. pylori*. Several months later, gastroenterology specialists again dilated the esophagus, now to 18mm, without resistance and

noted at that time an intact Nissen with persistent small hiatal hernia. Broad workup for the patient's continued symptoms was conducted at this time, including abdominal ultrasound, hepatobiliary iminodiacetic acid scan, and upper GI esophagram study. Results from these tests were notable for lack of any concerning biliary findings. The esophagram did show distal esophageal narrowing at the level of the fundoplication concerning for spasm vs. possible stricture (**Figure 2**). The patient was started on diltiazem at this time for suspected esophageal spasm. Esophageal pH testing was unable to be completed as patient could not tolerate the examination. Further testing, including esophageal manometry, showed incomplete lower esophageal sphincter (LES) relaxation in all swallows and esophagogastric junction outflow obstruction. The patient then underwent EGD with botox injection without improvement, suggesting that his fundoplication



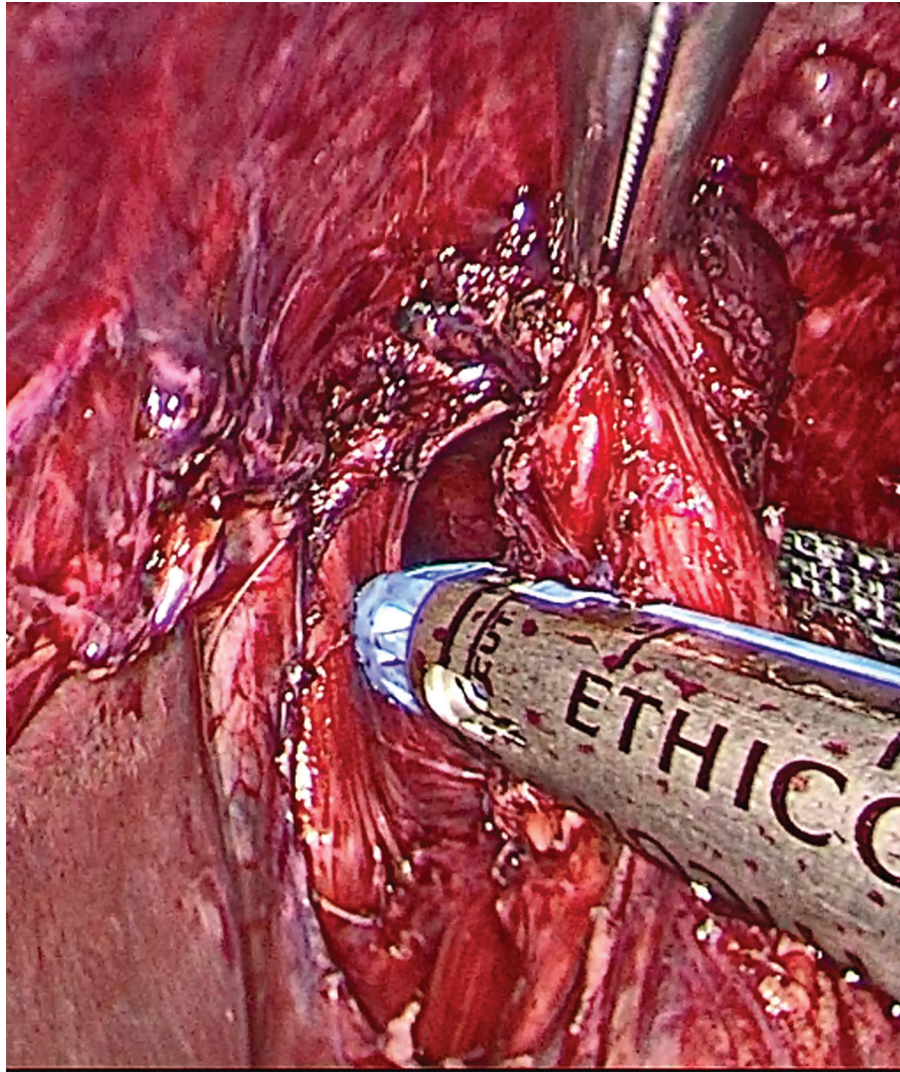
**Figure 2.** Pre-operative esophagram demonstrating distal esophageal narrowing at the level of the fundoplication.

was too tight. At this time, surgical intervention for possible revision of his prior fundoplication was planned.

Patient was positioned on the operating table in supine position and general anesthesia was induced. The abdomen was prepped and draped in the usual sterile fashion, and a veress needle and optical trocar entry technique was used to enter the abdominal cavity in the left periumbilical position. Following insufflation, the patient was adjusted to steep reverse Trendelenburg and two additional 5-mm trocars were placed, one in the left flank and one in the right flank. Upon inspection of the abdominal cavity, adhesions were noted from the omentum to the anterior abdominal wall as well as diaphragmatic hiatus.

Further adhesions were seen between the stomach and the anterior abdominal wall surrounding the prior gastrotomy site. These were dissected via sharp and blunt dissection. The site of prior gastrotomy was then taken down with a 45 mm endoscopic linear cutting stapler. At this time, the fundoplication as well as a moderate sized hiatal hernia could be visualized. The prior fundoplication was found to be dissociated and scarred in spiral fashion such that the posterior aspect of the fundoplication adhered to the crus of the diaphragm while the anterior aspect was 6cm distal. This resulted in a long-segment stricture. The posterior fundoplication was dissected off the esophagus via use of ultrasonic energy device and sharp dissection with endoscopic scissors. A gastric





**Figure 3.** The wedge resection of the gastric portion belonging to the former posterior wrap of the Nissen fundoplication.

wedge of this posterior fundoplication was then resected with use of a 45 mm endoscopic linear cutting stapler (**Figure 3**). Because the posterior wrap was adhered to the crus, this resection prevented the same esophageal stricture from recurring. The resection resulted in a Toupet-type partial posterior fundoplication at the gastroesophageal junction. At this time, the hiatal hernia was repaired primarily with 2-0 silk in a simple interrupted fashion, followed by a 2-point pexy of the esophagus to the 3 o'clock and 6 o'clock positions of the crus. At conclusion of the case, an EGD was performed, at which time saline leak test confirmed integrity of the two gastric staple lines. EGD also revealed a nearly normal omega-shaped flap valve at the gastroesophageal junction without evidence of stricturing.

The patient tolerated this procedure well. He was placed on a post-fundoplication diet, involving clear liquids only for 1 to 2 days, followed by full liquids for 1 to 2 days, pureed foods for 7 days, and soft ground diet for 5 weeks, with advancement to regular diet after 6 weeks postoperatively. The patient was discharged home on postoperative day 2. He has subsequently followed up in clinic with resolution of his dysphagia and without apparent complications at 8 months postoperatively, but will require longer follow up to ascertain the success of the operation.

## DISCUSSION

In the last 30 years, Nissen fundoplication has now become one of the most common operations performed

by pediatric surgeons in the United States, with the most common indication being GERD.<sup>4</sup> The Nissen fundoplication is not without its long-term complications, however. In one retrospective review of pediatric patients undergoing laparoscopic Nissen fundoplication, the redo rate amongst highly experienced surgeons was found to be 3%.<sup>3</sup> This study spanned the first 10 years that the Nissen fundoplication was implemented in the pediatric population, ultimately including 1050 patients.<sup>5</sup> A different review with an expanded follow-up period of 11 months to 19 years, showed that laparoscopic Nissen fundoplication in infants and children had a recurrence rate of 15.4%.<sup>3</sup> Specifically, subsequent dysphagia from excessively tight fundoplication is noted in 2% to 12% of patients postoperatively.<sup>3</sup> Bowel obstruction secondary to adhesions is seen at a similar rate in the postoperative population at 2% to 10%, a range consistent across both open and laparoscopic surgeries.<sup>3</sup> Risk of this complication is increased when additional procedures such as gastrotomy are performed at the time of the index case.<sup>5</sup>

Overall, fundoplication revision in the pediatric population is not uncommon. Refractory GERD and dysphagia were cited as indications for revision. A systematic review examined 930 laparoscopic antireflux surgeries performed for GERD from 1990 – 2010 that subsequently required revision surgery.<sup>6</sup> The most common revision at 70% of the redo surgeries, was a repeated Nissen fundoplication, with less often performed surgeries including Toupet partial fundoplication (17%) and hiatal repair without fundoplication (4%).<sup>6</sup> None of the redo surgeries described a gastric wedge resection for conversion to partial fundoplication. Interestingly, the mean interval from initial operation to revision was 45.5 months, ranging from 2 to 360 months.<sup>6</sup>

An additional retrospective study from one academic center focused on 72 pediatric patients who underwent laparoscopic fundoplication revision surgery over a 7.5 year period.<sup>7</sup> The method of revision for each redo surgery was described in detail. The most common method described a careful dissection to completely take down the prior fundoplication and identify gastroesophageal junction, followed by reapproximation of the crura and recreation of the 360 fundoplication.<sup>7</sup> Again, a stapled gastric wedge resection was not described in these cases.

While the rate of redo surgery does appear to be significantly higher in the pediatric population compared to the adult, most research and reviews have only examined complications within several months to years of the index operation. We performed a PubMed search for case

reports on presentation of dysphagia >10 years after initial Nissen fundoplication in the pediatric patient population. From this, we discovered one case report involving a 70 year-old male presenting with dysphagia after Billroth I and Nissen fundoplication several decades prior.<sup>8</sup> No cases were identified in which the patient was an infant at time of index operation. In our case, the patient was diagnosed as having a fundoplication too tight nearly 20 years after his original operation, performed when he was < 1 year old. During the case, the fundoplication was found to have migrated cephalad, with the posterior portion adhered to the diaphragmatic crus. We elected to convert this patient's Nissen to a partial posterior fundoplication both to alleviate the patient's dysphagia and to prevent reflux that would likely result from simply taking down the Nissen. Given the increased rate of both immediate and delayed postoperative complications following laparoscopic Nissen fundoplication compared to that in the adult population, it may be prudent to keep remote surgical history in mind when interviewing adult patients with chronic or acute-on-chronic upper GI complaints.

## CONCLUSION

Pediatric Nissen fundoplication for GERD is a common operation for infants. Long-term complications are possible, but not presented in large abundance in the literature. While refractory GERD is the most common cause for revision, delayed dysphagia from fundoplication deformation is possible as we present in this case. A complete anatomic and physiologic work-up should be completed and revisional surgery should be considered on a case-by-case basis depending on presenting symptoms and comprehensive evaluation.

## References:

1. Leung L, Wong CWY, Chung PHY, et al. Laparoscopic Nissen fundoplication for gastro-oesophageal reflux disease in infants. *Pediatr Surg Int*. 2015;31(1): 83–88.
2. Slater BJ, Rothenberg SS. Fundoplication. *Clin Perinatol*. 2017;44(4):795–803.
3. Lobe TE. The current role of laparoscopic surgery for gastroesophageal reflux disease in infants and children. *Surg Endosc*. 2007;21(2):167–174.
4. Madiwale MV, Sahai S. Nissen fundoplication: a review of complications for the rediatrician. *Clin Pediatr (Phila)*. 2015; 54(2):105–109.

5. Rothenberg SS. The first decade's experience with laparoscopic Nissen fundoplication in infants and children. *J Pediatr Surg.* 2005;40(1):142–147.
6. Symons NRA, Purkayastha S, Dillemans B, et al. Laparoscopic revision of failed antireflux surgery: a systematic review. *Am J Surg.* September 2011;202(3):336–343.
7. Celik A, Loux TJ, Harmon CM, Saito JM, Georgeson KE, Barnhart DC. Revision Nissen fundoplication can be completed laparoscopically with a low rate of complications: a single-institution experience with 72 children. *J Pediatr Surg.* December 2006;41(12):2081–2085.
8. Lai CN, Krishnan K, Kim MP, Dunkin BJ, Gaur P. Pseudoachalasia presenting 20 years after Nissen fundoplication: a case report. *J Cardiothorac Surg.* 7 July 2016;11(1):pubmed.ncbi.nlm.nih.gov/27387670/.