

Appendix-Sparing Transabdominal Preperitoneal Laparoscopic Hernioplasty for a De Garengeot's Hernia. Video Demonstration

Alberto Gómez-Portilla, MD, PhD, Elena Merino, MD, Eduardo López de Heredia, MD,
Alberto Gareta, Esther Diago

ABSTRACT

Background and Objectives: Less than 300 cases of a De Garengeot's hernia have been published. This rare femoral hernia with the vermiform appendix included appears almost exclusively on the right side, mainly in females, and it generally debuts as an incarcerated femoral hernia. Although most of the times there is a concomitant appendicitis, clinical signs of peritonitis are absent. The wide use of radiologic exams has not favored its preoperative diagnosis, but been usually found incidentally during a surgical emergency. The best surgical approach to a De Garengeot's hernia is not totally defined and many critical questions still remain unanswered. Open surgery is considered the standard treatment procedure, but since the emergence of laparoscopy for incarcerated hernias, this is certainly an option.

Methods: We report the successful laparoscopic management of an 83-year-old woman who had been operated on her right inguinal hernia, with a Rutkow-Robbins' technique, 4 months earlier. She had noticed the protrusion of a lump in her right inguinal region for 2 months. Radiological studies were not conclusive. With a miss diagnosis of a recurrent incarcerated inguinal hernia, a minimal invasive endoscopic approach was performed. A representative case of this fully laparoscopic TAPP procedure is presented.

Results: The patient made an uninterrupted recovery. She left the hospital the day after in a stable condition and has enjoyed good health since.

Conclusion: A fully laparoscopic TAPP approach seems perfectly safe and feasible to treat this entity, and could be considered the first line alternative when enough expertise is available.

Key Words: De Garengeot's Hernia, TAAP, Laparoscopic Hernioplasty, Appendix, Femoral Hernia.

Citation Gómez-Portilla A, Merino E, López de Heredia E, Gareta A, Diago E. Appendix-sparing transabdominal preperitoneal laparoscopic hernioplasty for a de garengeot's hernia. video demonstration. CR^{SLS} e2020.00098. DOI: 10.4293/CR^{SLS}.2020.00098.

Copyright © 2021 by SLS, Society of Laparoscopic & Robotic Surgeons. This is an open-access article distributed under the terms of the Creative Commons Attribution-Noncommercial-ShareAlike 3.0 Unported license, which permits unrestricted noncommercial use, distribution, and reproduction in any medium, provided the original author and source are credited.

Disclosure: none.

Funding/Financial support: none.

Conflicts of interest: The author declares no conflict of interest.

Informed consent: Dr. Gómez-Portilla declares that written informed consent was obtained from the patient's for publication of this study/report and any accompanying images.

Address correspondence to: Alberto Gómez-Portilla, MD, PhD, University Hospital of Araba, Sede Santiago Apóstol, Vitoria, Alava, Spain. E-mail: agomezpor@gmail.com

BACKGROUND AND OBJECTIVES

The presence of a vermiform appendix within a femoral hernia has been known as De Garengeot's hernia, since the Paris surgeon Rene-Jaques Croissant de Garengeot¹ described this clinical picture in 1731, although he did not

perform an appendectomy on that occasion. The first appendectomy for a De Garengeot's hernia was performed by Hevin² in 1785. It is an extremely rare entity, with less than 300 cases published in the literature to date. The greater incidence of femoral hernias in women explains why this type of hernia appears almost exclusively on the

right side mainly in females, with a sex ratio of 13/1, women/men³. Although an asymptomatic painless groin swelling has been reported⁴, it debuts practically invariably in an emergency setting, as an incarcerated, not reducible femoral hernia with concomitant appendicitis. Clinical signs of peritonitis are usually absent. The acute appendicitis tends to be the consequence of the strangulation of the appendix by the rigid hernia neck. Although ultrasonography and computed tomography (CT) are widely used nowadays, the preoperative diagnosis of a De Garengeot's hernia remains uncommon and it is usually found incidentally during surgery. Open surgery is still considered the standard procedure, but the best surgical approach to a De Garengeot's hernia is not totally defined, and it poses a challenge for surgeons. Since minimal invasive video-endoscopic access techniques for the treatment of an incarcerated hernia have emerged⁵, these certainly constitute an option. In an acutely incarcerated hernia requiring an emergency operation, the endoscopic approach is uncommon and controversial, and even considered contraindicated. Many critical questions still remain unanswered: 1) what the best surgical treatment option is and whether a simultaneous appendectomy is needed or not; 2) when a herniorrhaphy or a hernioplasty repair may be undertaken; 3) whether to apply an open surgery versus a mixed or a total laparoscopic approach; 4) which laparoscopic technique is better: laparoscopic transabdominal preperitoneal procedure (TAPP) or total extraperitoneal procedure (TEP); 5) what type of mesh may be of use; and 6) whether the placement of a foreign material is safe in a potentially contaminated environment after an appendectomy. All these open questions may well have to be considered in each individual patient case.

METHODS

We report the successful laparoscopic management of an 83-year-old woman who was accepted to our clinic with an irreducible swelling in her right groin region associated with intermittent pain. She denied having other symptoms. She had been operated on a right inguinal hernia with a Rutkow-Robbins' procedure 4 months earlier, but a concomitant femoral hernia was not found during this surgical exploration. The patient had noticed the protrusion in her right inguinal region for 2 months. Since then the lump had maintained the same size. On examination there was a tender irreducible hernia on the right side. The ultrasonograph revealed a cystic space-occupying lesion in the right inguinal region. The CT imaging showed a tubular

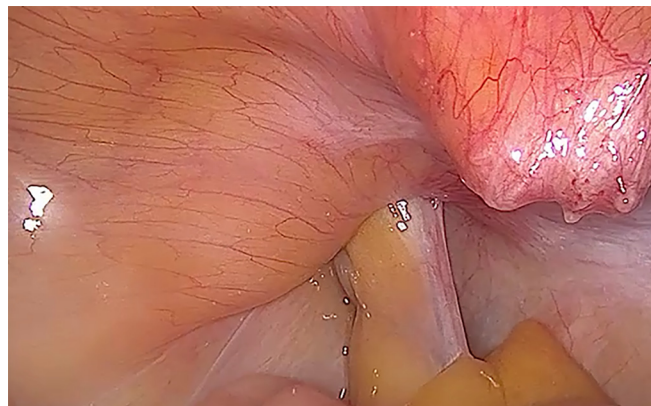


Figure 1. Laparoscopic view of a De Garengeot's hernia just below the plug mesh of a former inguinal hernioplasty.

structure as the cause of the palpable groin bulge, but it was not conclusive. With a misdiagnosis of incarcerated recurrent inguinal hernia, a minimal invasive endoscopic approach was performed. A representative clinical case of the procedure is presented. Upon laparoscopic inspection, the initial findings within the scope revealed a long pelvic appendix incarcerated slipping into the right femoral orifice just below the previous plug mesh (**Figure 1**). This favored a De Garengeot's hernia diagnosis. By pulling gently at the base of the mesoappendix we initially succeeded in a gradual repositioning of the appendix into the abdomen to a fixed point. Then, a TAPP approach was undertaken, the anterior parietal peritoneum was dissected and reflected to expose the right preperitoneal area. The hernia neck appeared on the medial side of the external iliac vein. A quelotomy using scissors and electrocautery was needed to dissect and loose the hernia sac away, by incising and opening the hernia's ring after notching the Gimbernat's ligament in a ventro-medial direction. Visceral mobilization and hernia reduction could be obtained safely. Then, an appendix-sparing laparoscopic hernia's sac reduction was undertaken. The tip of the appendix process, which lay inside the sac, appeared to be quite healthy when it was reintroduced in the abdominal cavity, and the appendix could be finally spared and left in place. Then, the wide exposition of the preperitoneal space allowed for a comfortable and safe repair of the right femoral hernia with a TAPP hernioplasty procedure using a 3D light Bard mesh fixed with CapSure tackers.

RESULTS

The patient made an uninterrupted recovery, and she left the hospital the day after in a stable condition. She

has enjoyed good health since, and when last seen in May 2020, there was no weakness at the femoro-crural ring.

DISCUSSION

Long-standing presentation of a De Garengeot's hernia is rarely reported.⁶ Its preoperative diagnosis is challenging, and only a few reports of positive ultrasonography or CT preoperative diagnosed cases are available in the literature.⁷⁻⁹ Femoral hernias present the highest rate of incarceration and strangulation, therefore requiring early surgical repair. The surgical management of a De Garengeot's hernia is controversial, but we highlight laparoscopy as a valuable technique in the treatment of this unusual presentation of this rare subset of femoral hernias. The laparoscopic approach can lead to an accurate assessment of both the hernia sac and the appendix vermiform simultaneously.¹⁰⁻¹¹ Most of the times a combined approach has been used, the appendix is removed laparoscopically and the femoral hernia is repaired with open surgery.^{4,11-14} In case of gross contamination from appendicitis, an elective subsequent elective open or laparoscopic repair, once the septic problem resolved is suggested.

Laparoscopic approaches without the need for conversion to an open repair, either TEP¹⁵ or TAPP^{5,6,11,16,17}, have seldom been communicated. The question naturally arises whether in such cases the removal of the vermiform appendix constitutes the best way to treat the femoral hernia and how to proceed with the gap. The practice of most surgeons could be to remove the appendix. But, is there an absolute necessity to perform an appendectomy after the division of Gimbernat's ligament, or should a reintroduction in the abdominal cavity¹³ suffice if it looks healthy enough? Recent literature¹⁴ supports the use of a mesh for the repair of the hernia when local contamination is negligible, provided there is no peritonitis, appendix perforation, or abscess formation.

Once the diagnosis of a De Garengeot's hernia has been established, open surgery is still considered the standard procedure. Unlike some authors who preconize a staged treatment of the pathology,¹⁸ we recommend a laparoscopic TAPP approach without delay from the beginning. The TAPP procedure provides the possibility to inspect the pelvic and intraabdominal cavity in toto and to select the best alternative surgical procedure. After the hernia is reduced, the time period dedicated to

repair the hernia represents an observation time for the detection of the viability of the incarcerated appendix. Afterwards, when the appendix looks healthy enough after this "test time", as in our case, we would suggest that it is undesirable to remove it, since there exists the danger to add some iatrogeny. On the contrary, if a concomitant appendicitis is present, laparoscopic appendectomy should be undertaken. Before our case, we have found only one report of a TAPP appendix-sparing laparoscopic hernioplasty for a De Garengeot's hernia.¹⁷ Probably, in a near future, more cases will be properly diagnosed preoperatively and could be treated on a programmed basis, according to our TAPP appendix-sparing laparoscopic hernioplasty.

CONCLUSION

We conclude that a fully laparoscopic TAPP procedure seems perfectly safe and feasible to treat this entity, and it could be considered a first line alternative when enough expertise is available, as it provides a short hospital stay, faster recovery, and lower morbidity rates than open surgery.

References:

1. Garengeot RJC. (1731) *Traite des opérations de chirurgie*. 2nd ed. Paris, France: Huart, 1731:369-371.
2. Hevin M. (1785) *Cours de pathologie et de thérapeutique chirurgicales*. Paris, France: Méquignon 1785:404-408.
3. Piperos T, Kalles V, Al Ahwal Y, Konstantinou E, Skarpas G, Mariolis-Sapsakos T. Clinical significance of de Garengeot's hernia: a case of acute appendicitis and review of the literature. *Int J Surg Case Rep*. 2012;3(3):116-117.
4. Ramsingh J, Ali A, Cameron C, Al-Ani A, Hodnett R, Chorushy C. De Garengeot's hernia: diagnosis and surgical management of a rare type of femoral hernia. *J Surg Case Rep*. 2014; rju008.
5. Leibl BJ, Schmedt CG, Kraft K, Kraft B, Bittner R. Laparoscopic transperitoneal hernia repair of incarcerated hernias: is it feasible? Results of a prospective study. *Surg Endosc*. 2001;15(10):1179-1183.
6. Al-Subaie S, Mustafa H, Al-Sharqawi N, Al-Haddad M, Othman F. A case of de Garengeot hernia: the feasibility of laparoscopic transabdominal preperitoneal hernia repair. *Int J Surg Case Rep*. 2015;16:73-76.
7. Filatov J, Ilibitzki A, Davidovitch S, Soudack M. Appendicitis within a femoral hernia: sonographic appearance. *J Ultrasound Med*. 2006;25(9):1233-1235.

8. Zissin R, Brautbar O, Shapiro-Feinburg M. CT diagnosis of acute appendicitis in a femoral hernia. *Br J Radiol.* 2000;73(873):1013–1014.
9. Fukukura Y, Chang SD. Acute appendicitis within a femoral hernia: multidetector CT findings. *Abdom Imaging.* 2005;30(5):620–622.
10. Shah A, Sira Janardhan HS. De Garengeot hernia: a case report and review of literature. *Indian J Surg.* 2013;75(Suppl 1):S439–S441.
11. Thomas B, Thomas M, McVay B, Chivate J. De Garengeot hernia. *JSLs.* 2009;13(3):455–457.
12. Ikram S, Kaleem A, Satyapal D, Muzaffar AS. De Garengeot's Hernia: a Rare Presentation of the Wandering Appendix. *BMJ Case Rep.* 2018;2018:bcr2017223605.
13. Comman A, Gaetzschmann P, Hanner T, Behrend M. De Garengeot hernia: transabdominal preperitoneal hernia repair and appendectomy. *JSLs.* 2007;11(4):496–501.
14. Tartaglia D, Cobuccio L, Musetti S, Decanini L, Galatioto C, Chiarugi M. Acute appendicitis complicating De Garengeot's hernia treated with combined laparoscopic-open technique: a case series and literature review. *Ann Ital Chir.* 2017;6:S2239253X17027268.
15. Beysens M, Haeck L, Vindevoghel K. Laparoscopic appendectomy combined with TEP for de Garengeot hernia: case report. *Acta Chir Belg.* 2013;113(6):468–470.
16. Legnani GL, Rasini M, Pastori S, Sarli D. Laparoscopic transperitoneal hernioplasty (TAPP) for the acute management of strangulated inguino-crural hernias: a report of nine cases. *Hernia.* 2008;12(2):185–188.
17. Allen BC, Kirsch J, Szomstein S. Case 187: De Garengeot hernia. *Radiology.* 2012;265(2):640–644.
18. Snoekx R, Geykens P. De Garengeot's hernia: acute appendicitis in a femoral hernia. Case report and literature overview. *Acta Chir Belg.* 2014;114:149–151.

